



# Impact of AI-powered remote monitoring on the management of emergency appointments



By Dr. Jean Guilloux

Private practice based in Gujan-Mestras (Bassin d'Arcachon) | Doctor in Dental Surgery in 1990 | CECSMO in 1993 | Using the Damon technique since 2006 | Monitoring my patients on DM since 2016 for Invisalign cases and 2020 for interceptive and fixed appliance cases

## Case study overview

Orthodontic treatment of adolescents with braces is often a real challenge for the practitioner, mainly because of the lack of visibility. Appointments are usually scheduled at bi-monthly intervals, a considerable amount of time during which many things can happen without our knowledge: hygiene problems, periodontal complications, and unanticipated clinical incidents, resulting in appointments taking longer than planned and disrupting the daily agenda. In other words, unpleasant surprises lead to longer appointments, patients waiting longer, longer working days, and, as a result, an inefficient practice and an unhappy team.

Many of these problems can be minimized, managed remotely, and, if not, at least anticipated and planned for.

The following case study illustrates how I overcame these common challenges by monitoring my treatments with Dental-Monitoring (DM) - a remote monitoring solution powered by artificial intelligence that enables me to carry out a weekly or bi-weekly check between appointments. This monitoring is carried out using patient scans taken at home with their smartphones using the DM app and DM Scanbox Pro. The scans are processed by artificial intelligence to control image quality, detect over 130 clinical situations, and alert me to clinical incidents. This new approach enables me to be more efficient by anticipating problems, managing them remotely whenever possible, and, above all, proactively managing treatment.

## Initial situation



Fig.1 - Extraoral front and side photos at rest and with a smile before treatment

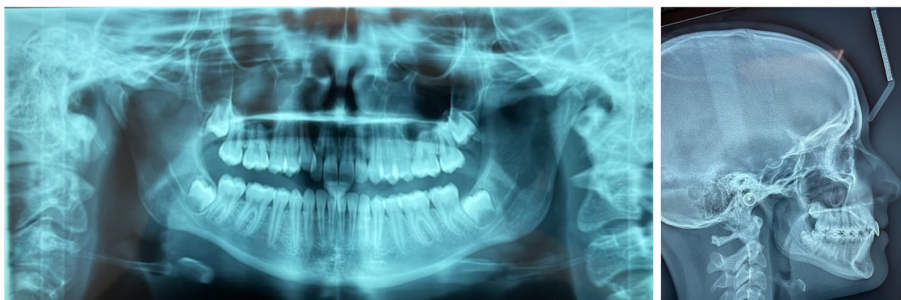

Fig.2 - OPG and profile telerradiography before treatment

## History

The patient was 14 years and 5 months old at the time of consultation. She was referred by her dentist to correct the malposition of the UR3.

## Diagnosis

- Class I left, deviation of the upper inter-incisal midline to the left
- Class II right
- Cross bite UR3/LR3
- Insufficient space for the eruption of UR3
- Small rotations of mandibular incisors

# A DentalMonitoring Case Study

By Dr. Jean Guilloux

## Initial situation

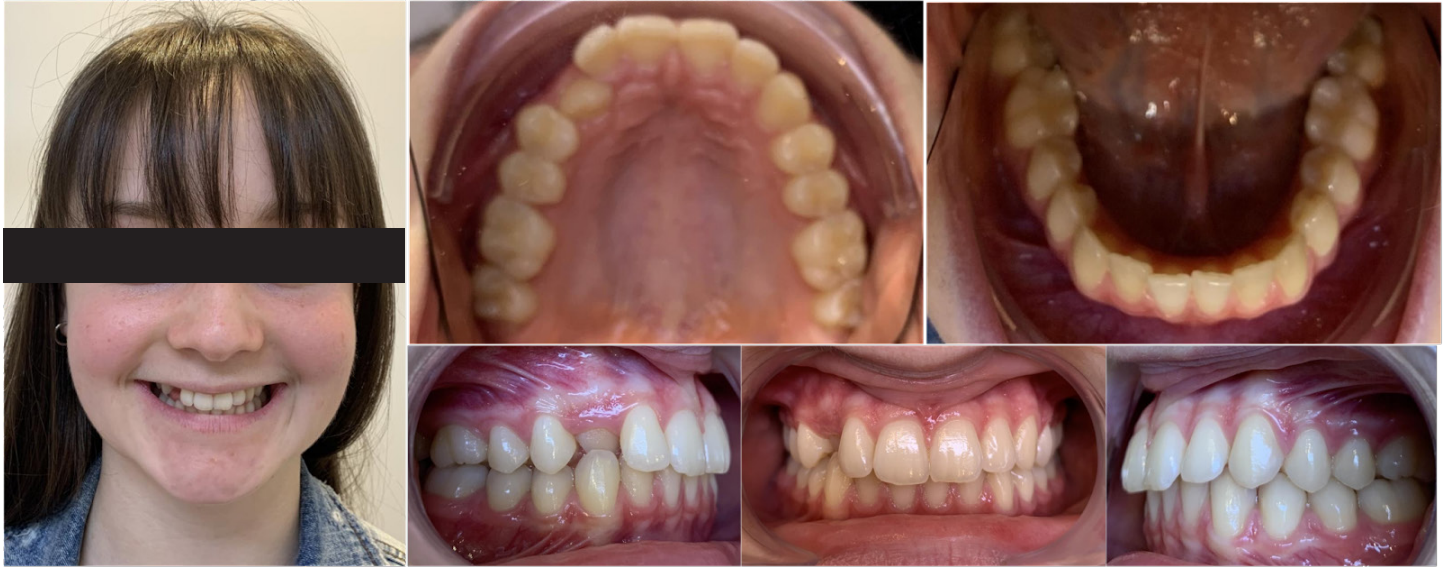

Fig.3 - Front extra-oral photos and intra-oral photos at the start of treatment

## Treatment summary

<b>Treatment duration</b>	2.5 years (02/24/2021 - 08/28/2023)
<b>Total number of appointments</b>	14
<b>Number and nature of emergency appointments</b>	3 (014 protruding wire and Wilson bimetric appliance irritating the gingiva)
<b>Number of appointments avoided thanks to DM</b>	5 (4 incidences of open self-ligating clip managed remotely, and an incidence of tie loss but archwire in place so the patient was reassured via DM messaging and no appointment was needed)
<b>Scan frequency</b>	2 weeks

## Final situation

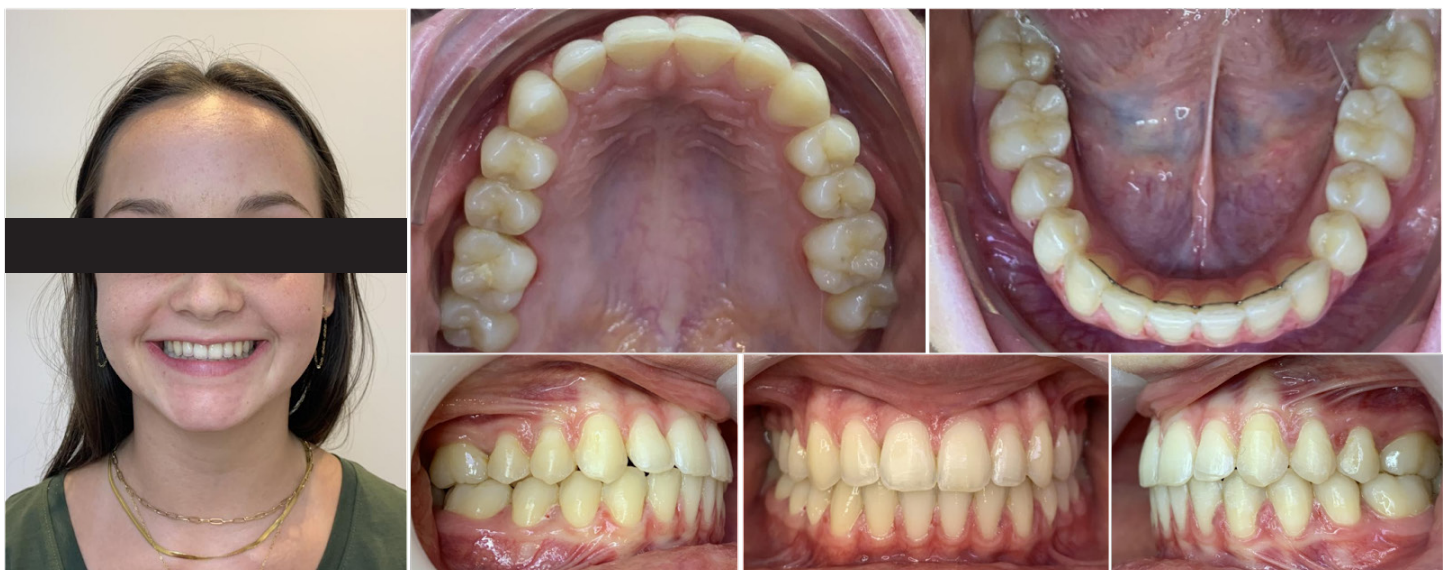

Fig.4 - Front extraoral photos and end-of-treatment intraoral photos



# A DentalMonitoring Case Study

By Dr. Jean Guilloux

## How has DM helped me manage this case more effectively and with greater serenity?

There are three main aspects to be highlighted in this case:

- 1. Better management of emergencies** - Remote management of clinical incidents such as open self-ligating clips (fig. 5) enabled me to react instantly to minimize the side effects of this type of incident and avoid an unnecessary appointment, as it was easy for the patient to manage at home. Even emergencies that can't be managed remotely by the patient, such as tie loss/degrading (fig. 6), don't always require an emergency visit, because in this particular case, the archwire was still in place. All we had to do was monitor it until the next appointment.
- 2. Better hygiene management** - Two reasons: Firstly, thanks to the Hawthorne effect (when patients know they are being monitored, they are more inclined to comply). Secondly, thanks to the reminder messages and targeted communication that patients receive on their app (fig. 7), we don't need to repeat the same instructions at every visit, which in itself saves time and avoids the risk of confrontation with patients and their parents.
- 3. Proactive treatment management** - DM allows me to set "treatment goals" so that I'm informed when a patient reaches treatment milestones - for example, canine Class I and archwire passivity. When these goals are achieved (or not) within a specific timeframe of my choosing, DM alerts me and I call the patient in to move on to the next stage of treatment ( fig. 8). This approach enables me to offer appointments only when they are clinically necessary, and thus to optimize my planning.

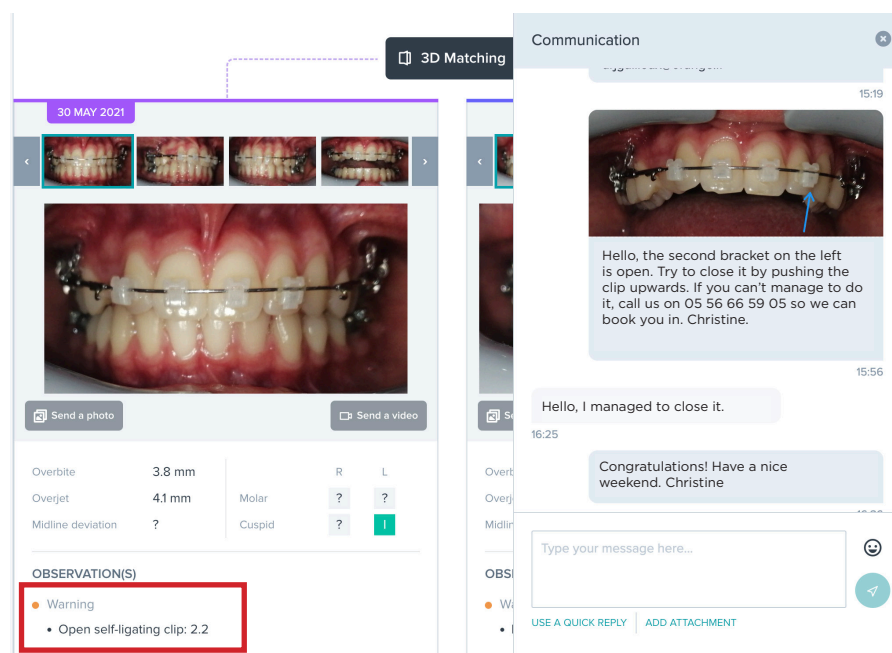


Fig.5 - Screenshot of DentalMonitoring dashboard showing AI detection of an open self-ligating clip on the UL2 and communication with the patient via the DM chat

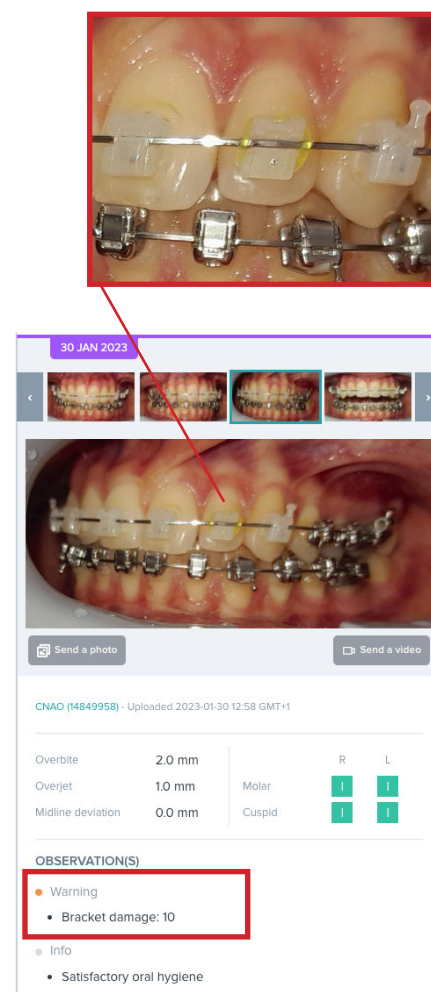
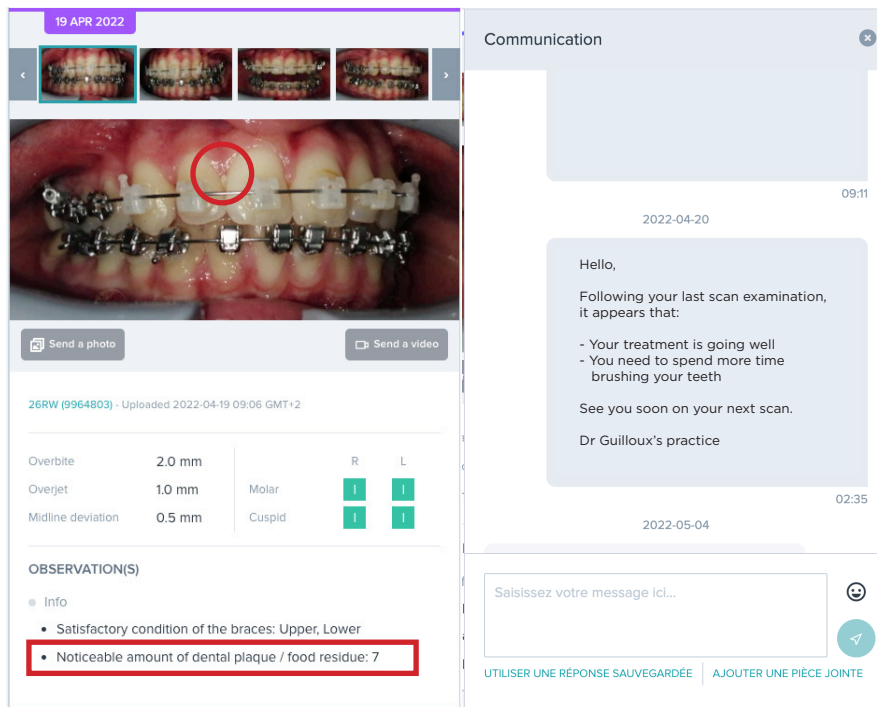


Fig.6 - Screenshot of DentalMonitoring dashboard showing AI detection of a damaged attachment

# A DentalMonitoring Case Study

By Dr. Jean Guilloux



## Conclusion

This case study clearly illustrates the benefits of using artificial intelligence to monitor patients at home, overcoming the limitations of the traditional approach to orthodontic treatment management. Thanks to DM, all contingencies were identified at an early stage and, in this case, managed entirely remotely. It's easy to see from this case study how, when this concept of treatment monitoring and management is applied to all patients, the impact is significant on several levels: on practice efficiency, treatment quality, the patient experience, and, perhaps most importantly, the serenity of the teams.

Fig.7 - Screenshot of DentalMonitoring dashboard showing AI detection of a hygiene problem

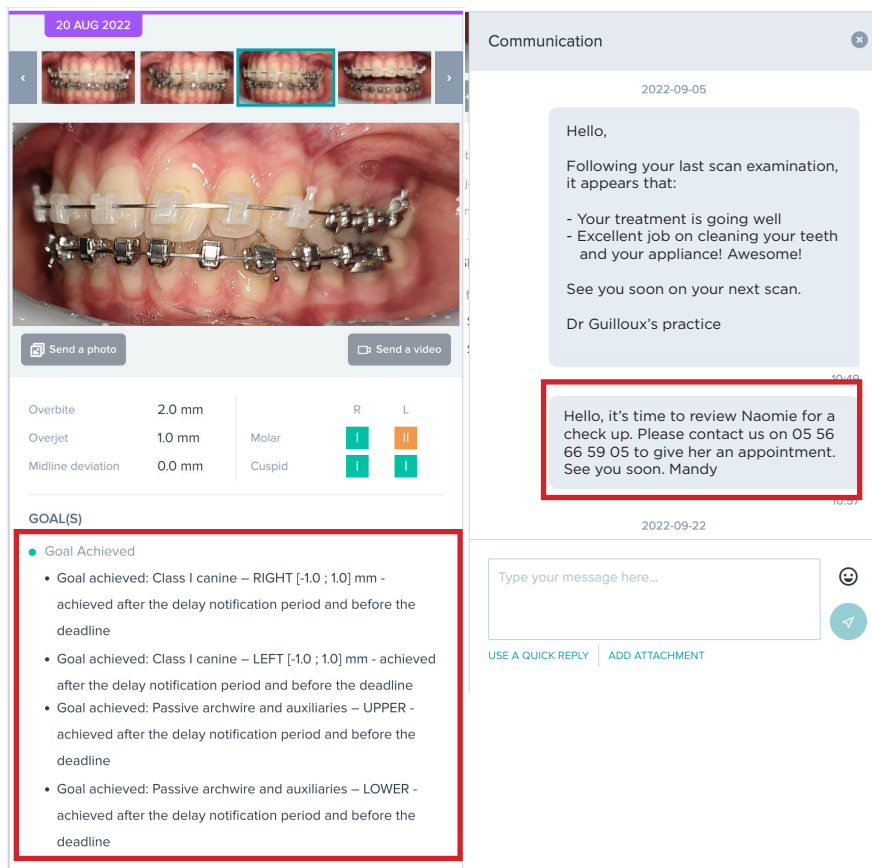


Fig.8 - Screenshot of the DentalMonitoring dashboard showing when we received the "objectives achieved" notification for Class I canine occlusion and passive archwires.